

**Gastroenterology Laboratory  
Division of Gastroenterology**

**ESOPHAGOGASTRODUODENOSCOPY**

- Esophagogastroduodenoscopy diagnostic
- Esophagogastroduodenoscopy with biopsy
- Esophagogastroduodenoscopy with variceal banding
- Esophagogastroduodenoscopy with sclerotherapy
- Esophagogastroduodenoscopy remove foreign body
- Esophagogastroduodenoscopy diagnostic / caustic ingestion

Instrument: \_\_\_\_\_

Endoscopist(s): \_\_\_\_\_

Anesthesia:

- General
- None

Indications:

Moderate sedation:

- Demeral \_\_\_\_\_ mg.,
- Versed \_\_\_\_\_ mg.
- Other \_\_\_\_\_

Specimen Removal: [ ] None [ ] Other \_\_\_\_\_

Findings:

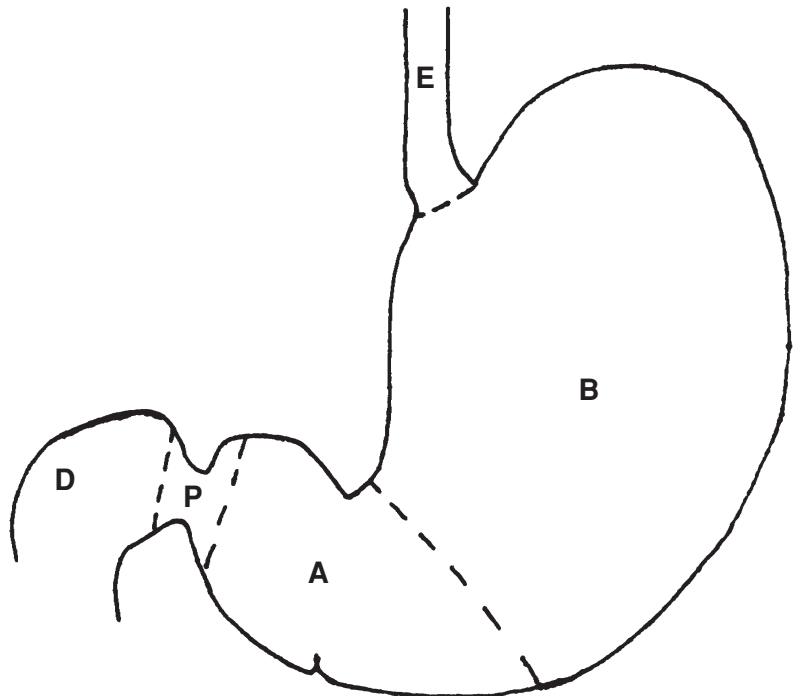
Esophagus:

Gastric Body:

Gastric Antrum:

Pylorus:

Duodenum



EBL: [ ] None [ ] Other \_\_\_\_\_

Interpretation:

Post Procedure Diagnosis:

Time \_\_\_\_\_ Date: \_\_\_\_/\_\_\_\_/\_\_\_\_ Performing MD: \_\_\_\_\_ MD # \_\_\_\_\_